



Renal Actinomycosis in Presence of Renal Stones in a Patient with End Stage Renal Disease

Mohammad Reza Pourmand¹, Sanaz Dehghani², Marziyeh Hadjati²,
Farid Kosari³, Gholamreza Pourmand^{2*}

¹ Department of Pathobiology, School of Public Health, Tehran University of Medical Sciences, Tehran, IR Iran

² Urology Research Center, Tehran University of Medical Sciences, Tehran, IR Iran

³ Department of Pathology, Tehran University of Medical Sciences, Tehran, IR Iran

ARTICLE INFO

Article type:

Case Report

Article history:

Received: 27 Sep 2012

Revised: 20 Oct 2012

Accepted: 24 Nov 2012

Keywords:

Actinomycosis

Kidney Transplantation

Kidney Calculi

ABSTRACT

Renal actinomycosis is a rare infection, and actinomycosis mostly acts as a normal flora in mouth, colon and vagina. We present a case of 56 years old man, who referred to our center for renal transplantation with kidney stone and diagnosed with renal actinomycosis. This case has risen possibility of rare infection that can be considered in the setting of renal transplantation.

- **Please cite this paper as:** Pourmand MR, Dehghani S, Hadjati M, Kosari F, Pourmand GR. Renal Actinomycosis in Presence of Renal Stones in a Patient with End Stage Renal Disease. *J Med Bacteriol.* 2012; **1** (3, 4): pp. 62-65.

Introduction

Human actinomycosis is a rare saprophyte bacterial infection. The most common species is *Actinomyces israelii*, which normally exists in the mouth, colon and vagina. This organism can cause infections among patients with immune suppression. In this case, patients with end stage renal disease diagnosed with multiple renal stones and furthermore after nephrectomy found that patient is suffering from renal actinomycosis.

Case Report

A 56 years old man was referred to our center for renal transplantation. He had a history of recurrent multiple renal stones. Three months prior to admission, he had common cold-like symptoms with flank pain and subsequently diagnosed with renal failure. He had been on hemodialysis three times a week. He had several procedures such as bilateral renal stent placement and shockwave lithotripsy. His past medical and social history was negative.

On admission, he was afebrile, PR: 75, RR: 14/min., BP: 130/70 mmHg with no abnormal finding on physical examination.

Laboratory examination showed: anemia (Hb: 10.6 gr/dl), elevated erythrocyte sedimentation rate: 88 mm/hour, elevated C-reactive protein (+++), increased creatinine: 7.5 mg/dl, increased blood urea nitrogen: 108 mg/dl, FBS: 113 mg/dl, Uric Acid: 7.1 mg/dl.

Urinalysis showed Pyuria (with many white blood cells), hematuria (with many red blood cells), glucosuria (+) and bacteriuria (moder-

ate). Ultrasonography showed multiple stones in both kidneys.

In order to prevent post-transplantation infection, the two stents removed and right nephrectomy performed. The kidney was pyelonephritic and was adhered to the surrounding tissues.

The kidney sent for pathologic examination. On microscopic study, pyelonephritis, atrophic changes and one cystic lesion reported; furthermore, *Actinomyces* rods were identified in the tissue specimen (*Figure 1*).

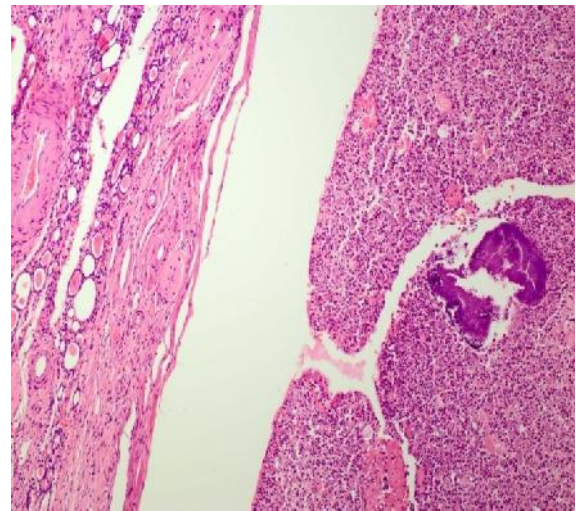


Figure 1. Low power view of the kidney with evidence of severe chronic pyelonephritis (left) and exudative material containing *Actinomyces* colony (Right); Hematoxylin Eosin X100

Antibiotic coverage with doxycycline 100 mg twice daily prescribed for the patient for four weeks. After completing the course of medication, the second nephrectomy performed and the patient underwent renal transplantation from a live donor and his recovery

was uneventful and the patient discharged in a stable condition with creatinine 1.2 mg/dl.

Discussion

A. israelii is an anaerobic gram-positive filamentous bacterium which inhabits the mouth, gut and vagina. It is harmless until a breach happens in the host's defense system. The organism is able to produce cervicofacial osteomyelitis and abscess (60%), pneumonia with emphysema (15%), peritoneal and pelvic abscess (25%) (1). Once infection established, the host mounts an intense inflammatory response in the form of suppuration or granulation; fibrosis may then follow (2).

This slow-growing organism spreads; frequently ignoring tissue planes, and invades surrounding tissues or organs (3). Hematogenous dissemination to distant organs may occur (3-5) whereas lymphatic dissemination is unusual (5, 6).

Common laboratory findings in actinomycosis include: anemia and mild leukocytosis, elevated erythrocyte sedimentation rate and C-reactive protein (3). A gram-stained smear of the specimen (tissues or aspiration materials) may demonstrate the presence of beaded, branched, gram-positive filamentous rods, suggesting the diagnosis of actinomycosis (6). The route of involvement of the kidney includes the bloodstream and direct expansion from contiguous organs such as gastrointestinal tract in abdominal actinomycosis or through diaphragm in pulmonary disease (7), although primary source could not always be determined.

A. israelii is seldom found in the urine (8), although pus cells could be seen in large numbers and secondary infection may be present.

The definite diagnosis is generally based on histologic identification (7) and occasionally by culture (3); however, its diagnosis rarely anticipated preoperatively (7-9). Early diagnosis and treatment with antibiotic for 8 weeks is important for minimizing the morbidity of the disease (9, 10).

A. israelii is relatively sensitive to many antibiotics and accurate treatment will cure the disease. Since uremic patients are immunocompromised, performing further examinations to diagnose such infections is always necessary.

In order to eradicate the source of infection and prevent serious post-transplant complications in patients whose pyuria cannot be treated by usual modalities, nephrectomy would be necessary before transplantation because they have to use immunosuppressive drugs afterwards.

Acknowledgement

None declared.

Conflict of Interest

None declared conflicts of interest.

References

1. Khalaff H, Srigley JR, Klotz LH. Recognition of renal actinomycosis: nephrectomy can be avoided. Report of a case. *Can J Surg* 1995; **38** (1): 77.
2. Bala S, Narwal A, Gupta V, et al. Actinomycotic osteomyelitis of mandible masquerading periapical pathology. *J Oral Health Comm Dent* 2011; **5** (2): 97-9.

3. Henrikus EF, Pederson L. Disseminated actinomycosis. *West J Med* 1987; **147** (2): 201-4.
4. Juhasz J, Galambos J, Surjian L. Renal actinomycosis associated with bilateral necrosing renal papillitis. *Int Urol Nephrol* 1980; **12** (3): 199-203.
5. Lippes J. Pelvic actinomycosis: a review and preliminary look at prevalence. *Am J Obstet Gynecol* 1999; **180** (2 pt 1): 265-9.
6. Lely RJ, van Es HW. Case 85: Pelvic actinomycosis in association with an intrauterine device. *Radiology* 2005; **236** (2): 492-4.
7. Morgan RJ, Molland EA, Blandy JP. Renal actinomycosis. *Eur Urol* 1977; **3** (5): 307-8.
8. Patel BJ, Moskowitz H, Hashmat A. Unilateral renal actinomycosis. *Urology* 1983; **21**(2): 172-4.
9. Horino T, Yamamoto M, Morita M, et al. Renal Actinomycosis mimicking renal tumor. *South Med J* 2004; **97** (3): 316-8.
10. Fauci AS, Braunwald E, Kasper DL et al, 2008 *Harrison's principles of internal medicine*, 17th ed. McGraw-Hill Professional, New York, p. 996.